



II Encontro ASBAI - BRAGID

Case Report

Flavia Carvalho

- ❖ **ID:** GSS (Birth: 02/24/2013), female, born and resident in Rio de Janeiro
- ❖ **Medical History:** After 3 days of life started intermittent fever associated with irritability. With 21 days of life was hospitalized for one month where she received numerous antibiotics treatments without clinical response (sustained fever and leukocytosis from 15,000 to 44,000, anemia and thrombocytosis). Evolved with mucocutaneous candidiasis and difficult weight gain. No positive urine and blood cultures. After 2 months of life, she was transferred to our hospital (IFF-FIOCRUZ) for PID investigation.
- ❖ **Gestational history and childbirth:** No relevant events, negative maternal serology
- ❖ **Family history:** Denied consanguinity, early deaths, autoimmune diseases
- ❖ **Vaccination history:** BCG and B hepatitis (without BCG mark)

On admission, the patient presented malnutrition, recurrent diarrhea and mucocutaneous candidiasis (armholes, genital and oral).

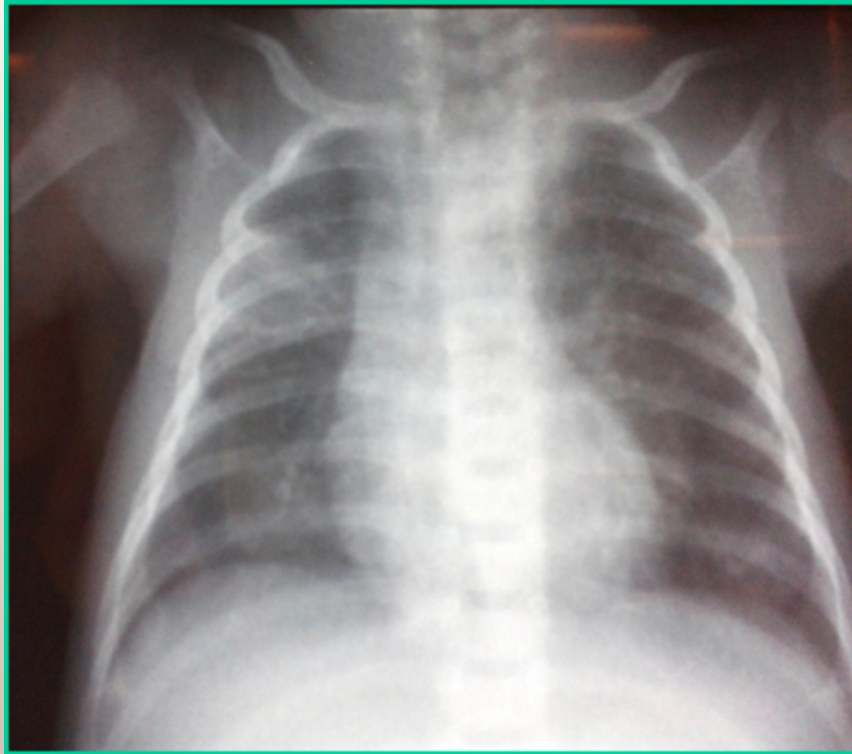
Laboratory

Date	WB	Baso	Eos	Meta	Mielo	Bast	Seg	Lin	Mono
March 2013 - 3 months	30500	0	1	0	0	6	41	48	4

Hm	Hb	Ht	Plat	CRP
2.87	8.46	25%	845,000	1.0

IgG	IgM	IgA	IgE
207 <p3	< 6.59	< 6.38	<4.32

T cell CD3	T cell CD4	T Cell CD8	CD4/CD8	B cell CD19	B cell CD20	NK CD16	NK CD56
90.6% 15335 > p90	65.1% 11019 > p90	25.5% 4316 > p90	2.55	3% 508 p10 - p50	3% 507	7.2% 425 P10-25	7.1% 419 P10-25



- Treated with: antibiotics for pneumonia, intravenous human immunoglobulin, fluconazole
- After resolution of the infection was kept with prophylaxis with antifungal and antibiotic

➤ 9 months of age , hospitalization for pneumonia and sepsis
Hemoculture: *Serratia marcescens*
Bronchoscopy - M. Tuberculosis, fungal, Pneumocystis jiroveci: all negative

- Intermittent fever since third day of life
- Recurrent diarrhea
- Severe malnutrition
- Developmental delay
- No hepatomegaly, no splenomegaly
- Candidiasis since newborn with resolution only after prophylaxis with antifungal drugs
- Hypogammaglobulinemia
- Leucocytosis (15.000-44.000)
- Sepsis: hemoculture - *Serratia marcescens*



- ✓ Several sweat tests failure
- ✓ DHR normal

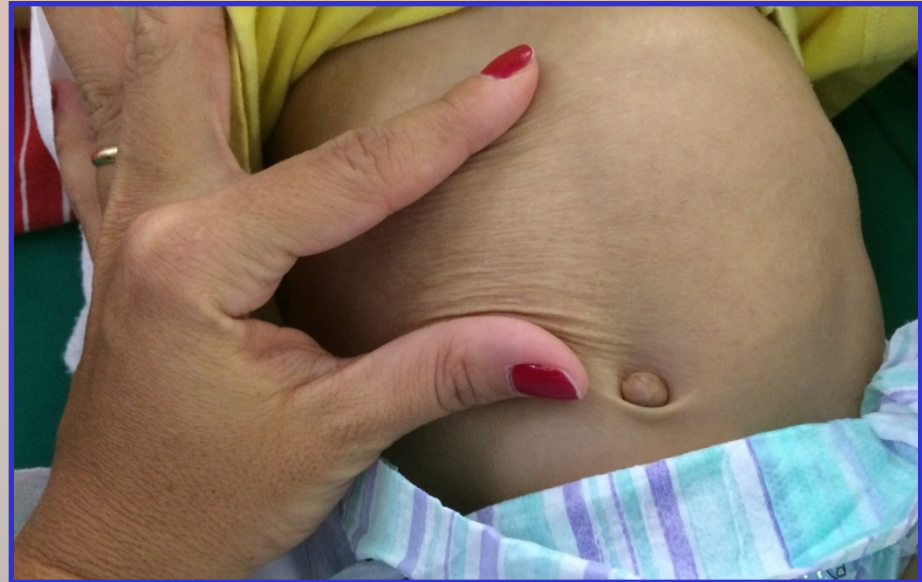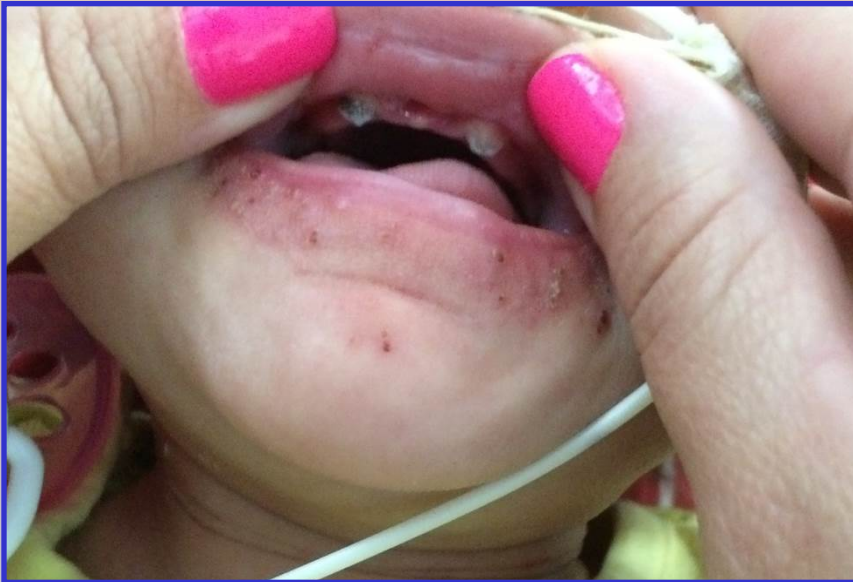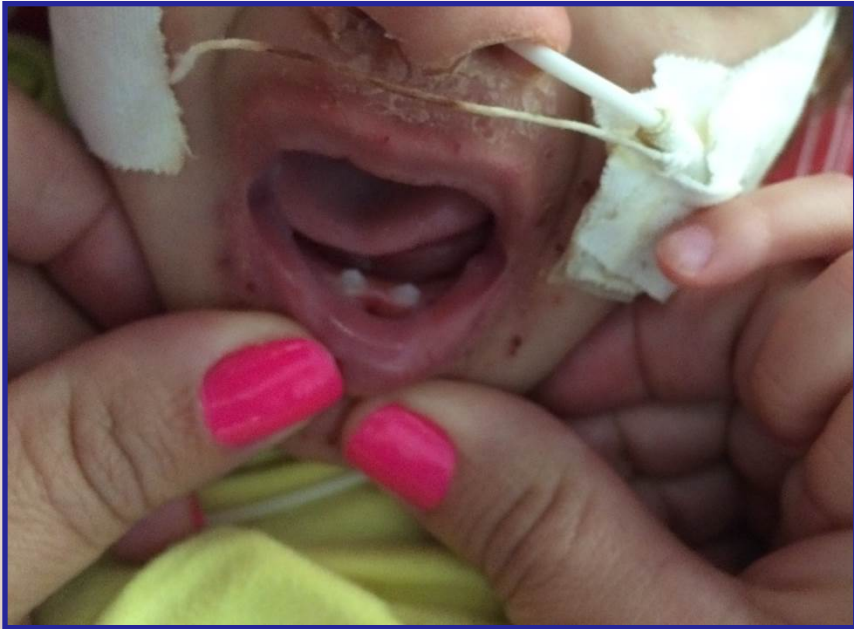Date	IgG	IgM	IgA	IgE
→ 05/08/13 – 3 m	207	<16.4	<6.38	<4.32
11/06/13 – 9m	504	589	<5.75	<4.1
04/29/14 – 1y 2 m	589	144	<6.38	<4.32
10/01/14 – 1y 8 m	993	391	33	<4.12
01/03/15 – 1y 11 m	683	230	36.3	<4.12

DATE	T Lin CD3	T Lin CD4	T Lin CD8	CD4/CD8	B Lin CD19	B Lin CD20	NK CD16	NK CD56
05/08/13	90.6%	65.1%	25.5%		3%	3%	7.2%	7.1%
3m	15,335	11,019	4,316	2.55	508	507	1,503	1482
	> p90	> p90	> p90		p10 - p50		>p90	
07/23/14	90.4%	64.3%	25.9%	2.5	2.4%	2.4%	5.4%	5.4%
1 y 5 m	15,067	10,715	4,328		459	501	1,035	1,035
	>p90	p>90	P>90		< p10		> p90	

- Switched memory B cells: 2.8%
- T CD4 lymphocytes: naive – 91.3%, memory: 8.3%, efector: 0.4%
- T CD8 lymphocytes: naive – 94.4%, memory: 5.5%, efector: 0.1%
- Low $\gamma\delta$ T cells; DP e DN normal
- T and B: normal proliferation

✓ CD40 e CD40L normal expression (Flow cytometry)

	COMPLICATIONS	EXAMS
1 year and 4 months	<ul style="list-style-type: none"> • <u>Hospitalization</u>: seizures not well controlled with medication, without associated infection. 	Myelogram: Discrete granulocyte dysplasia without any other relevant phenotypic results
1 year and 7 months	<ul style="list-style-type: none"> • <u>Hospitalization</u>: Tonic-clonic seizures associated with pneumonia and refractory septic shock. Negative hemoculture. 	<p>CT brain scan: Incipient calcifications of bilateral nuclei basis. Diffusely accentuated sulci and fissures.</p> <p>Normal exams last year (11 months)</p> <p>Brain MRI: diffuse and bilateral cerebral atrophy, especially frontotemporal</p>
1 year and 11 months	<ul style="list-style-type: none"> • <u>Hospitalization</u>: <ul style="list-style-type: none"> - Seizures and Pneumonia - Pneumonia - acute gastroenteritis and dehydration 	CSF: PCR for Enterovirus, EBV and herpesvirus 6, all negative.

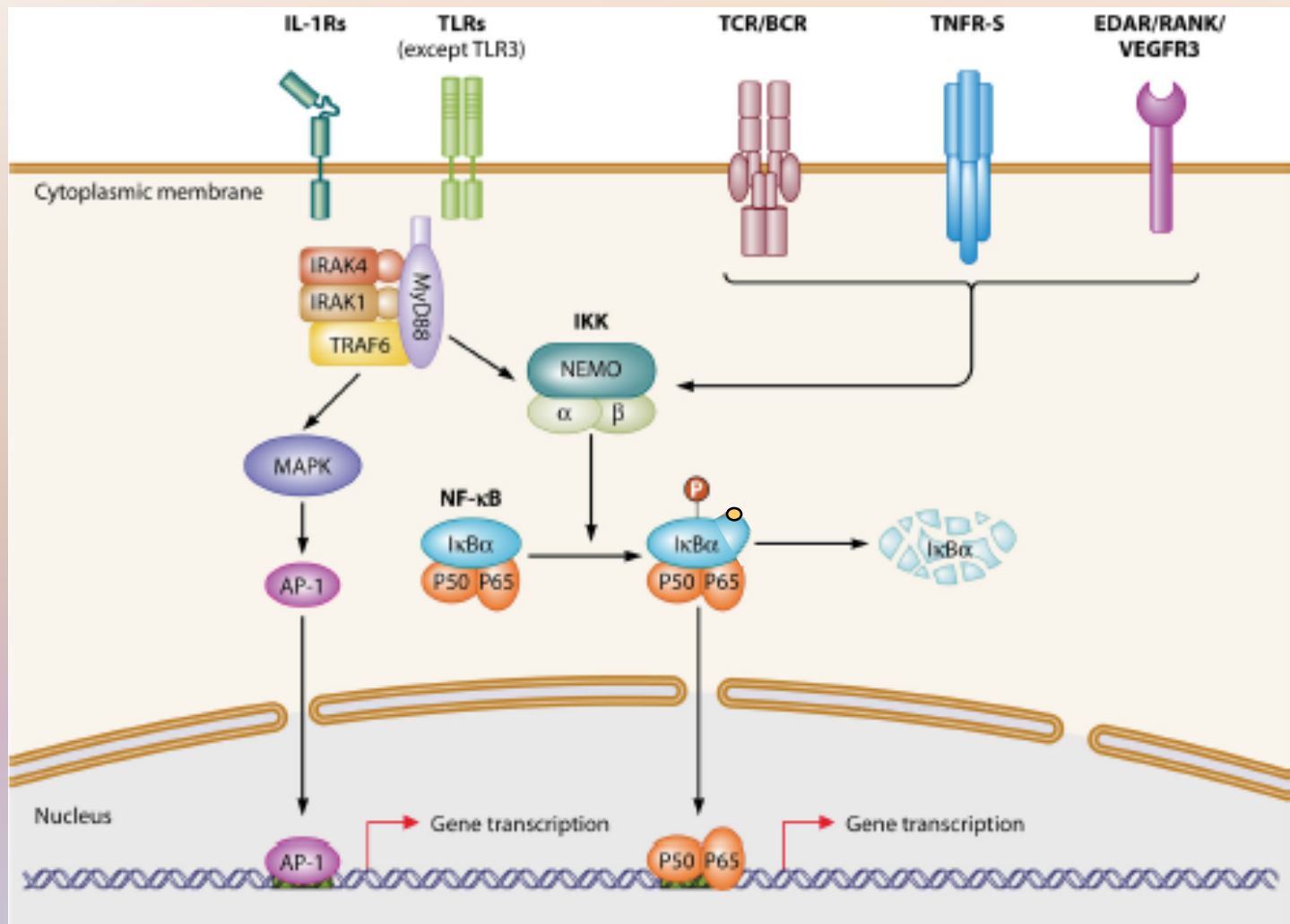


2 years and 2 months

- Hospitalization: lobar pneumonia
 - No complications during gastrostomy.
 - Hepatomegaly and pancytopenia.
 - Transferred to IPPMG for evaluation with hematology
 - Abdominal sepsis
 - Pulmonary sepsis
-
- Hemocultures negatives.
 - AARB negative
 - Bone marrow biopsy with negative culture for typical, atypical and mycobacteria microorganisms

Death (June 13th 2015) with 2 years and 4 months

07/22/2015: after exome sequencing was found an AD mutation at NFKBIA gene (IKB α), c.110T > G:p.M37R (Bosco).





Alergy and Immunolgy Service

Celso Ungier, MD
Sandra Bastos, MD
Paula Lauria, MD
Liziane Nunes, MD
Abelardo Bastos, MD

Immunology Laboratory -
Zilton Vasconcelos, MSc/PhD

Parasitic and infectious
diseases

Nutrition

Pneumology

Pediatry

Dermatology

Hematology/ Imunology
IPPMG

Antônio Condino Neto

João Bosco Filho